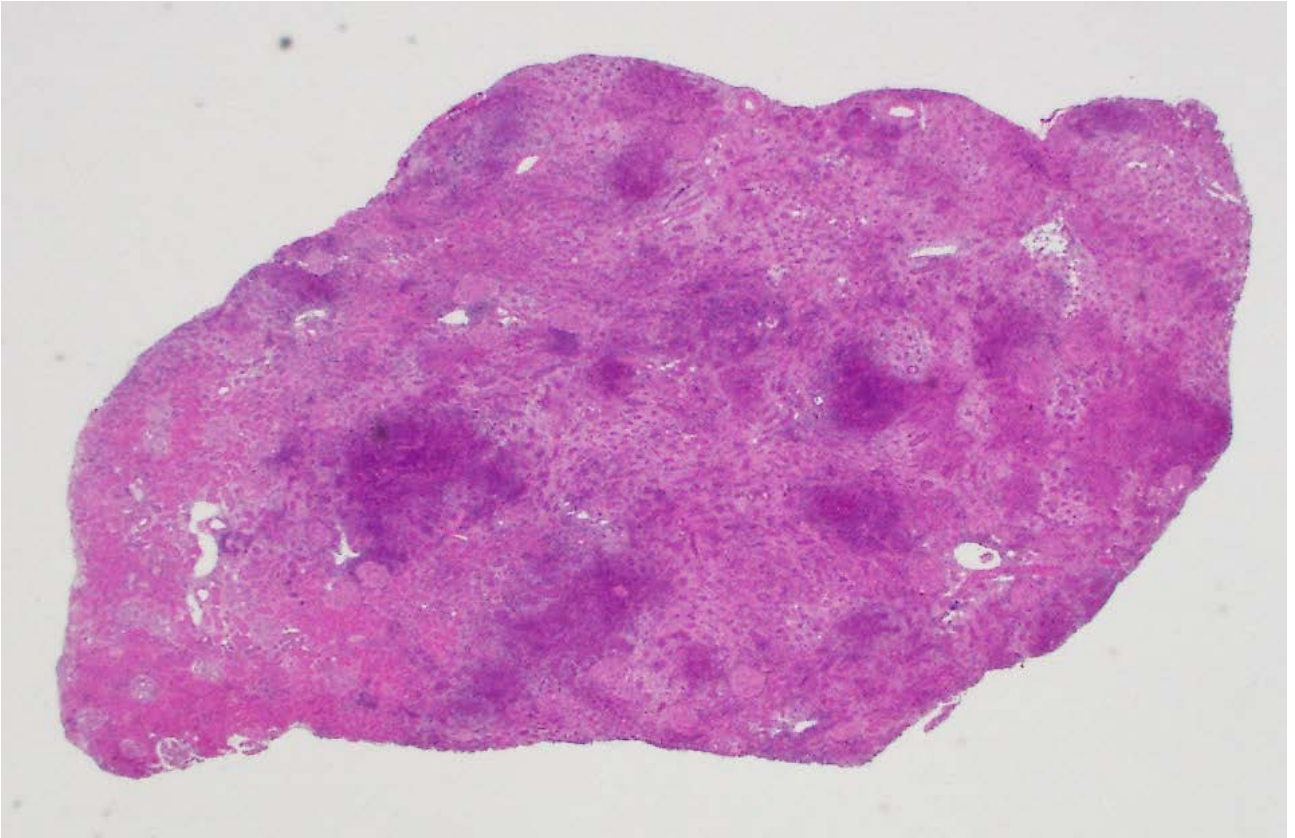
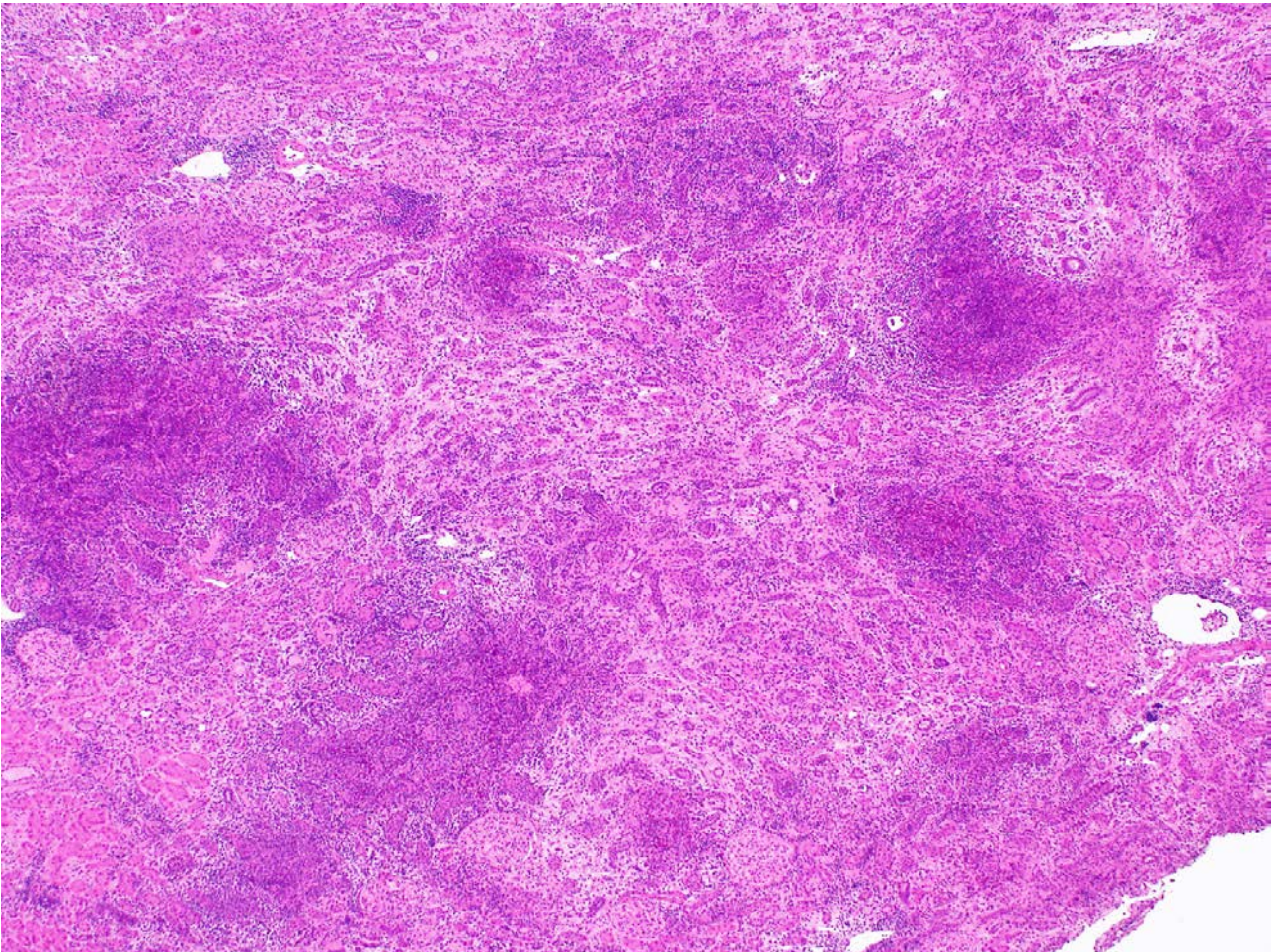


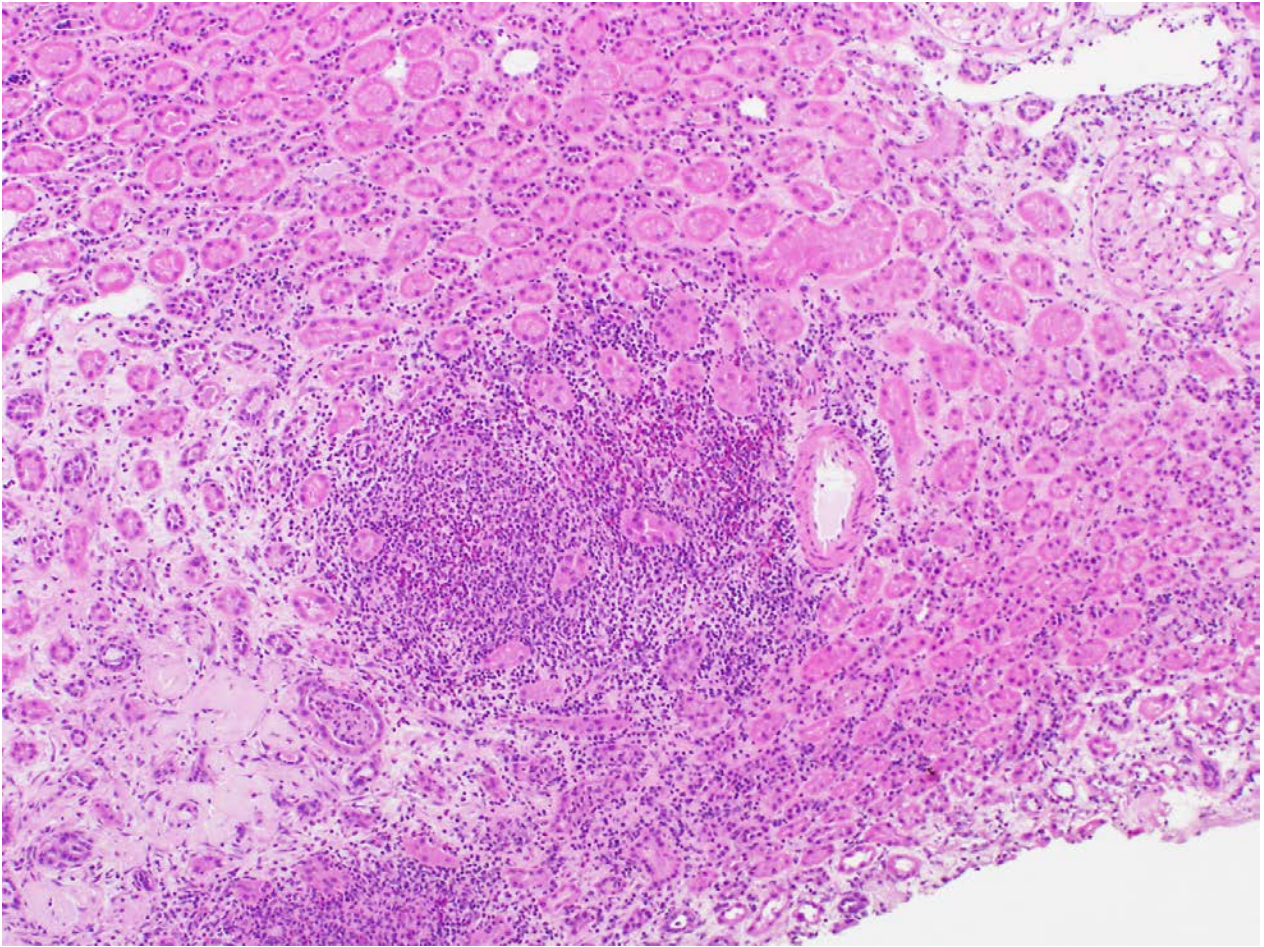
腎部分切除生検
HE染色 弱拡大



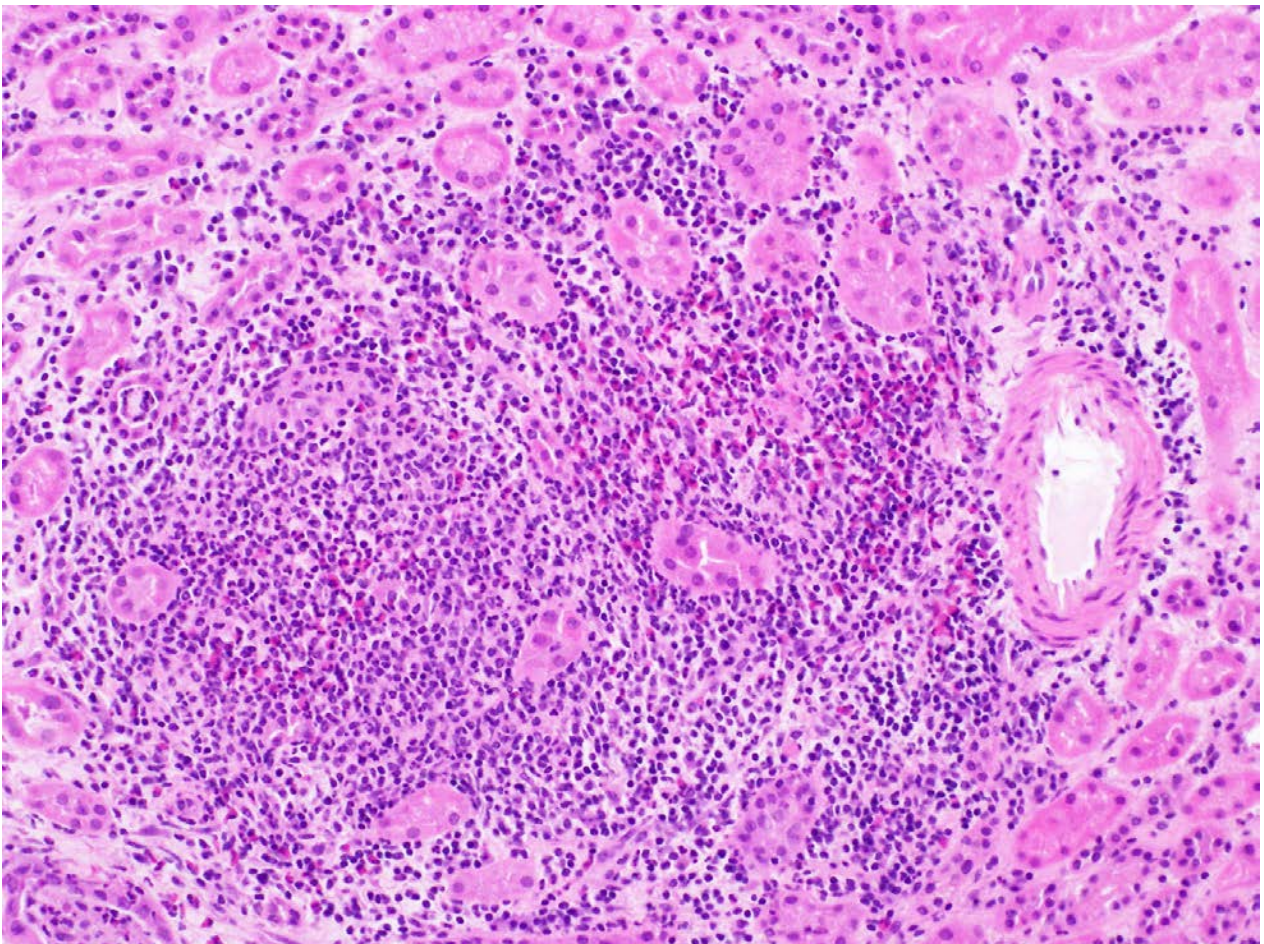
弱拡大 (少し拡大を上げて)



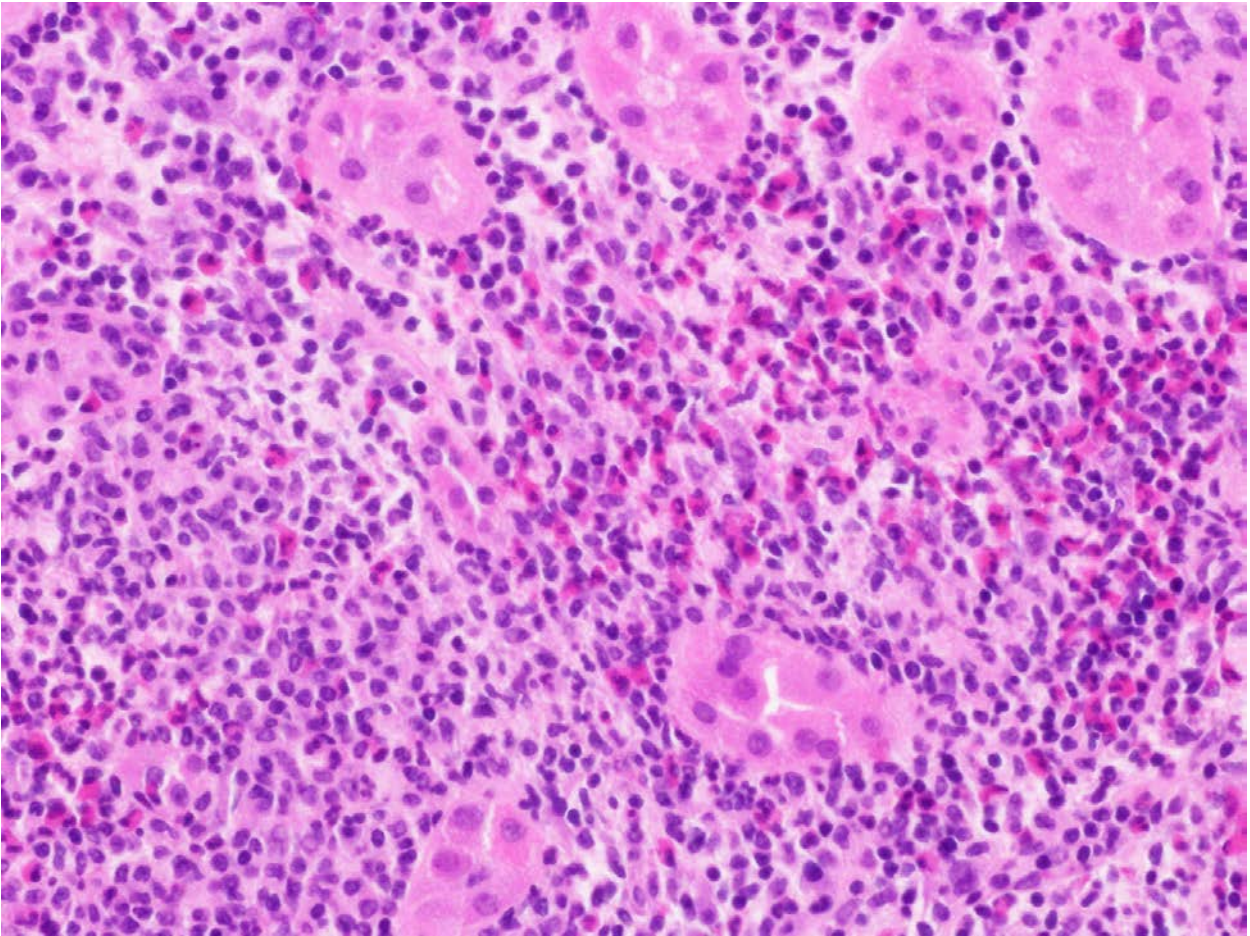
中拡大



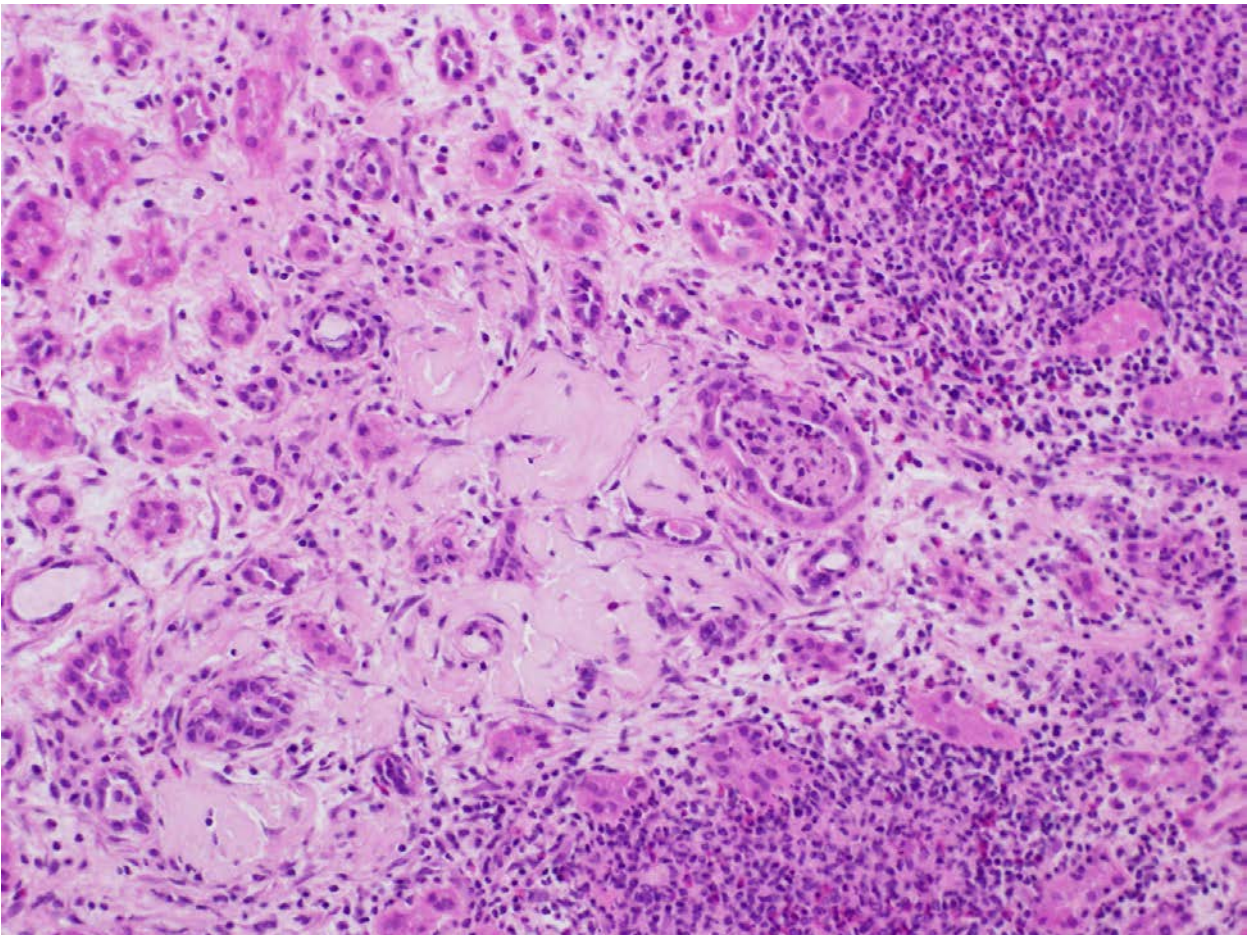
強拡大1-1



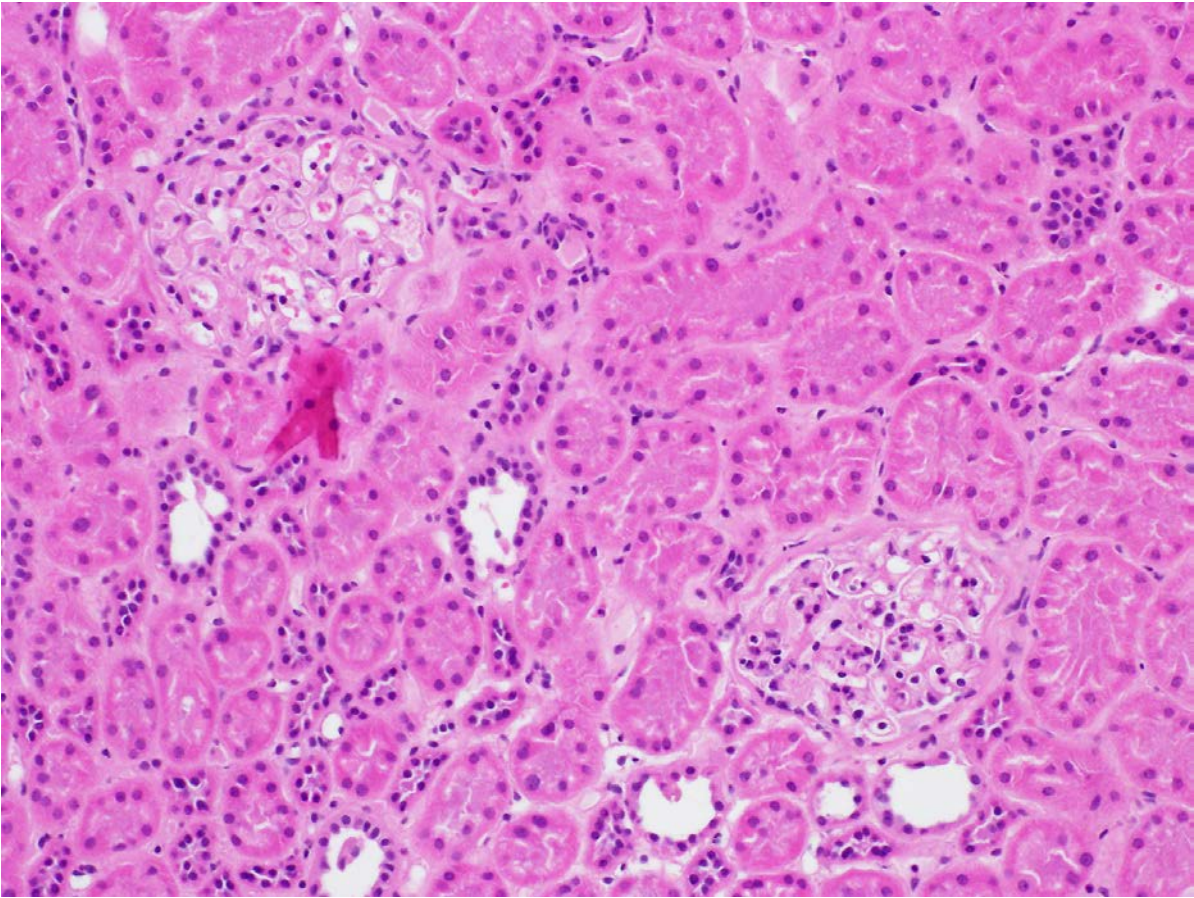
強拡大1-2



強拡大 アミロイド



強拡大 糸球体



強拡大 尿細管

